

PAEDIATRIC SEIZURES

Learners Guide

Author **Peter Tormey**

(Edits by the DFTB Team)

fellows@dontforgetthebubbles.com

PRE READING

Blog posts:

<https://dontforgetthebubbles.com/first-afebrile-seizure/>

<https://dontforgetthebubbles.com/consept-eclipse-status-epilepticus/>

<https://www.stemlynsblog.org/jc-enter-sandman-which-agent-as-second-line-in-paediatric-status-epilepticus/>

Podcasts:

<https://www.paediatricemergencies.com/status-epilepticus/>

<https://pemplaybook.org/podcast/131/>

<https://broomedocs.com/2019/06/paediatric-status-epilepticus-debate/>

OUTLINE (USE THE SECTIONS THAT ARE RELEVANT FOR YOUR LEARNERS)

- **Basics (10 mins)**
- **Main Session: (4 x 15 minute) case discussions covering the key points and evidence**
- **Advanced case (1x15 minute)**
- **Simulation (30-45mins)**
- **Quiz**
- **Take home learning points**

CASE SCENARIO 1 (15 MINS)

A 7 year old boy called Simon is brought to ED by his parents. At approximately 7am they were awoken by noises coming from his room. They ran in and noticed that the left side of his face was jerking and he was drooling and making gurgling sounds. He wasn't responding to them.

The movements stopped after 2 minutes. He was drowsy for a few minutes after and had difficulty talking and expressing himself for 15-20 minutes after. They also noticed there was a slight drooping on one side of his mouth for 15-20 minutes.

He has now fully recovered and is bright and alert in ED with GCS 15/15 and a normal neurological exam.

What are some of the key elements of Simon's past medical history that you must ascertain?

How would you classify his seizure?

Are there clues in the history as to what specific seizure disorder he may have?

Would you perform any investigations at this point?

Does he need to be admitted?

Does he need treatment?

What follow up will you arrange?

CASE SCENARIO 2

Emily is a 4 year old girl brought to ED with episodes of disturbed sleep for the last 3 weeks. This is her 4th visit to ED. She was previously diagnosed with “night terrors” and reassured. Her mum is concerned because the episodes are now occurring each night, having previously been 1-2 per week.

Her mum has videos of the episodes, which she shows you. The events usually occur shortly after going asleep. In the videos Emily wakes from sleep, looks terrified and stares straight ahead. The episodes go on for 2-3 minutes. She usually vomits or retches towards the end of the episode. She goes back to sleep after. She is well during the day.

Her development is normal and she has no other medical history.

What could be going on here?

What interesting details in the history might lead you towards a specific diagnosis?

What could help differentiate between epileptic and non-epileptic events in this case?

What is the prognosis for these patients?

ADVANCED CASE SCENARIO 1

Emma is a 3year old girl with a background of refractory epilepsy and developmental delay. Her current medications include levetiracetam, sodium valproate, clobazam and lamotrigine.

She is PEG fed but has been vomiting up her feeds for the last 2 days and mum is unsure if her medications have been staying down.

She normally has up to 20 short seizures per day at home, but this has been increasing in the last 2 days.

You get a pre-alert from the ambulance service: Emma has been having a generalized tonic clonic seizure for 15 minutes. Her mum gave her buccal midazolam at 5 minutes but it has not had any effect.

The ambulance crew ask you if they can repeat the dose of buccal midazolam? Emma arrives in resus with the seizure ongoing.

What is your management plan?

Emma has had two doses of benzodiazepines.

What would be your next line agent?

Who else should you be calling at this stage?

The ConSEPT and EcLiPSE trials were published concurrently in May 2019. You decide to suggest these papers for your department's next journal club and to discuss what effect they will have on your department's practice. One issue you foresee is that a lot of the patients you see are already on maintenance levetiracetam.

Does this preclude children on maintenance levetiracetam from receiving IV levetiracetam in status epilepticus, as is the case with the use of phenytoin in patients who take it as maintenance treatment?

Emma's seizure terminated with the second line agent and she was admitted under neurology for IV fluids and ongoing management of her seizures until she could tolerated her medications by PEG again. In this case her status epilepticus was likely due to her vomiting up her medications.

Had Emma's seizure not stopped after the loading dose of phenytoin, what would your next steps be?

ADVANCED SCENARIO 2

Caroline is a 13 year old girl who present to ED with a first seizure. Her parents describe a generalized tonic clonic seizure that lasted 2-3 minutes.

She is an otherwise well girl who is doing well in school. The only concern in her past medical history is that she has been having frequent syncopal episodes for the last 12 months. She has been seen by her GP for this who reassured her that syncopal events were common in her age group and advised her to drink plenty of fluids and try and avoid triggers.

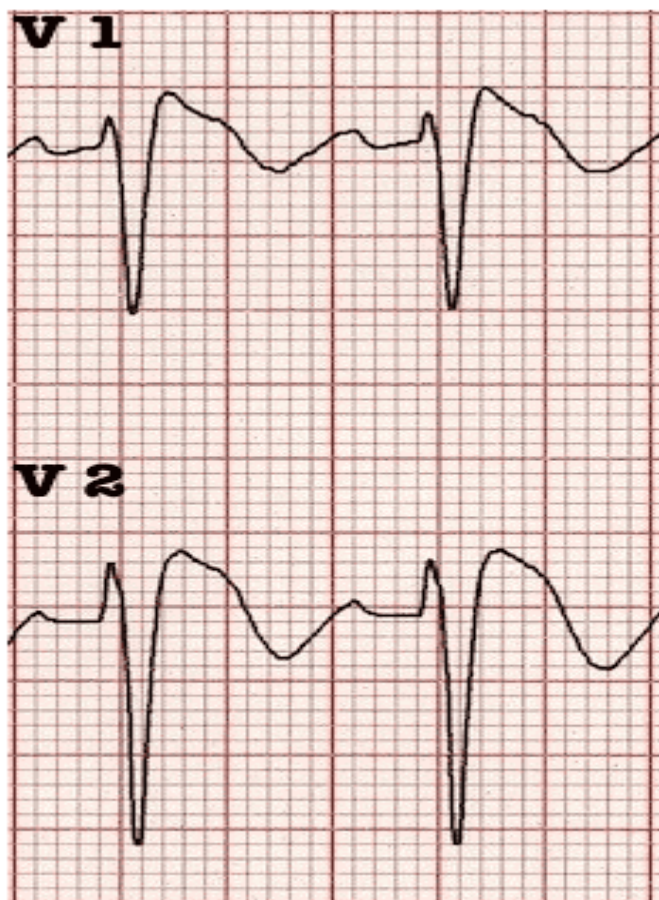
Her neurological exam is normal.

How would you proceed?

Are there any investigations you could perform in the department to investigate the syncopal episodes she reports?

Is there any link between syncope or arrhythmogenic events and seizures?

Caroline has an ECG performed which shows changes consistent with Type 1 Brugada Syndrome.



Caroline is admitted for further cardiac investigation and is scheduled for an ICD insertion. She also has an EEG, diagnostic for frontal lobe epilepsy, which is linked to ion channel abnormalities.

SIMULATION

http://www.oxforddeanery.nhs.uk/pdf/Paediatrics_8.pdf

QUIZ

Question 1.

Which symptom is more commonly seen with Panayiotopoulos Syndrome than night terrors?

- A** Staring
- B** Terrified expression
- C** Vomiting
- D** Thrashing of arms and legs
- E** Tachypnoea

Question 2.

Which of the following are side effects of phenytoin but not levetiracetam?

- A** Mood disturbance
- B** Cardiovascular toxicity
- C** Purple glove syndrome
- D** Gingival hypertrophy
- E** Stevens Johnson syndrome

Question 3.

Which of the following ECG findings are seen in Brugada Syndrome:

- A** Coved ST segment elevation in V1-3, >2mm
- B** Prolonged PR interval
- C** Negative T wave
- D** Saddleback ST elevation, >2mm
- E** LVH voltage criteria

Take Home Messages

- 1 Seizures are common in sleep and may present subtly- be wary of unusual events occurring around sleep and have a low threshold to investigate them for seizures
- 2 Make sure you have satisfied yourself there are no seizure red flags prior to discharging patients with a first afebrile seizure
- 3 Management of status epilepticus should proceed according to APLS and local guidelines
- 4 Levetiracetam may become a common choice second line agent for status epilepticus but for now it is advisable to continue to use phenytoin if you and your department have more familiarity with it.
- 5 It is important to identify and treat any precipitating cause for status epilepticus
- 6 An ECG should be performed in all patients presenting with seizures

REFERENCES

Clinical Practice Guidelines : Afebrile seizures [Internet]. [cited 2020 Apr 20].

Available from:

https://www.rch.org.au/clinicalguide/guideline_index/Afebrile_seizures/

Lyttle MD, Rainford NEA, Gamble C, Messahel S, Humphreys A, Hickey H, et al. Levetiracetam versus phenytoin for second-line treatment of paediatric convulsive status epilepticus (ECLIPSE): a multicentre, open-label, randomised trial. Lancet. 2019 May 25;393(10186):2125–34

www.uptodate.com/contents/seizures-and-epilepsy-in-children-classification-etiology-and-clinical-features?search=seizures%20in%20children&-source=search_result&selectedTitle=1~150&usage_type=default&display_rank=1

<https://www.ilae.org/education/infographics>

<https://dontforgetthebubbles.com/first-afebrile-seizure/>

Michael M, Tsatsou K, Ferrie CD. Panayiotopoulos syndrome: An important childhood autonomic epilepsy to be differentiated from occipital epilepsy and

- acute non-epileptic disorders. Vol. 32, Brain and Development. Elsevier; 2010. p. 4–9.
7. Ferrie CD, Grünewald RA. Panayiotopoulos syndrome: A common and benign childhood epilepsy. Vol. 357, Lancet. Elsevier Limited; 2001. p. 821–3.
8. Weir E, Gibbs J, Appleton R. Panayiotopoulos syndrome and benign partial epilepsy with centro-temporal spikes: A comparative incidence study. 2018 [cited 2020 May 4]; Available from <https://doi.org/10.1016/j.seizure.2018.03.002>
9. Mctague A, Martland T, Appleton R. Drug management for acute tonic-clonic convulsions including convulsive status epilepticus in children. Vol. 2018, Cochrane Database of Systematic Reviews. John Wiley and Sons Ltd; 2018.
10. Dalziel SR, Borland ML, Furyk J, Bonisch M, Neutze J, Donath S, et al. Levetiracetam versus phenytoin for second-line treatment of convulsive status epilepticus in children (ConSEPT): an open-label, multicentre, randomised controlled trial. Lancet. 2019 May 25;393(10186):2135–45.
11. Sandorfi G, Clemens B, Csanadi Z. Electrical storm in the brain and in the heart: Epilepsy and Brugada syndrome. Mayo Clin Proc. 2013 Oct 1;88(10):1167–73.
12. Camacho Velásquez JL, Rivero Sanz E, Velazquez Benito A, Mauri Llerda JA. Epilepsy and Brugada syndrome. Neurol (English Ed. 2017 Jan 1;32(1):58–60.

 fellows@dontforgetthebubbles.com