

# HEAD INJURIES

## Facilitators Guide

Author [Chris Odedun](#)

(Edits by the DFTB Team)

[fellows@dontforgetthebubbles.com](mailto:fellows@dontforgetthebubbles.com)

Author **Chris Odedun**

Duration **Up to 2 hrs**

Facilitator level **Senior trainee/ANP and above**

Learner level **Junior trainee/Staff nurse and Senior trainee/ANP**

Equipment required: **None**

## OUTLINE

- Basics (10 mins)
- Main session (2 x 15 minute) case discussions covering key points/evidence
- Advanced session (2 x 20 minutes) case discussions covering grey areas, diagnostic dilemmas; advanced management and escalation
- Simulation scenarios (30-60mins)
- Quiz (10 mins)
- Take home tips

We also recommend printing/sharing a copy of your local guideline for sharing admission criteria.

## PRE-READING FOR LEARNERS

It's helpful for the learners to have read something about the basics of head injury management before the session - these are some suggested resources for them to use

### **Basics of head injury assessment**

RCEMLearning module on head injury (September 2018)

### **Managing more serious head injuries**

OPENPediatrics "Introduction to Traumatic Brain Injury" (February 2016)

Neuroprotective strategies for severe traumatic brain injury  
(Paediatric FOAM)

DFTB "Traumatic Brain Injury" (2013)

Your department/region's guideline for managing head injuries in children.

## GLOSSARY

These are suggested terms for your learners to be familiar with, so that they get the most out of the learning

- 1-Primary injury/insult
- 2-Secondary injury/insult
- 3-Glasgow Coma Score/Scale
- 4-Concussion/post-concussion syndrome

## BASICS

Use of this section can be skipped if talking to an experienced audience

Head injuries form a wide spectrum of clinical presentations. At their most simple, they can be defined as any impact to the body, proximal to the cervical spine & neck, excluding trivial impact to the face. Practitioners seeing any patient with head injuries should devote time to understanding the **primary injury** - the mechanism, including its biomechanics.

### How did they get the initial injury?

They should also aim to develop expertise at identifying the cohort of patients at risk of **secondary injury**, from deviations of ICP, blood pressure, CO<sub>2</sub>, O<sub>2</sub> & glucose.

### What can we change here and now to make the patient's outcome as optimal as possible?

Head injuries are generally defined by conscious level (Glasgow Coma Score/ GCS) post-injury. Head injuries are a very common presentation for children to emergency departments. The vast majority are trivial or minor, requiring observation and/or discharge advice only.

Head injuries remain one of the most common causes of serious morbidity & mortality in children (and young adults). Practitioners need to become skilled at selecting the cohort who require imaging - which is well established as CT. This is the best modality commonly available to detect more serious injuries - typically contusions, intra/extra-cerebral bleeds & skull fractures. Practitioners should become familiar with clinical guidelines & decision-support resources (eg. NICE) to help guide which patients need imaging.

An even smaller proportion of these injured children will go on to require neurosurgical intervention. Here, the practitioner's role is to mitigate secondary injury, as above - with neuroprotective strategies.

Lastly, practitioners should be aware of the possibility of non-accidental injury, especially with regard to drowsy or unconscious infants, and remember that they have a role in safeguarding all children presenting to the ED, regardless of reason for presentation.

## Key FOAM

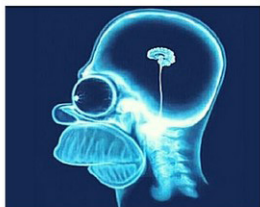NICE clinical guideline CG176 - head injury: assessment & early management esp. 1.3 & 1.4.9, 10, 11 + this review of the 2014 changes to indications for CT and more [Tessa Davis, Anna Ings (BMJ)]

### CT head?

Immediately in:

1 of:

- \* NAI
- \* Seizure (& no epilepsy)
- \* Initial assessment:  
GCS <14 or <15 in under 1s
- \* GCS <15 at 2 hrs from injury
- \* Sign of BOS#
- \* Focal neuro deficit
- \* Under 1 & bruise/swelling/lac >5cm



>1 of\*:

- \* LOC >5min
- \* Abnormal drowsiness
- \* >3 episodes of vomiting
- \* Dangerous MOI
- \* Amnesia >5min

\* if only 1: observe for 4 hrs and CT if more vomiting, abnormal drowsiness or GCS <14

## DFTB

Head injury: who to scan? (2013)

Franz Babl: PREDICT and head injuries (#DFTB2017)

## St Emlyn's

Devastating brain injury (2018)

Rick Body: anticoagulants and minor head injury (2012)

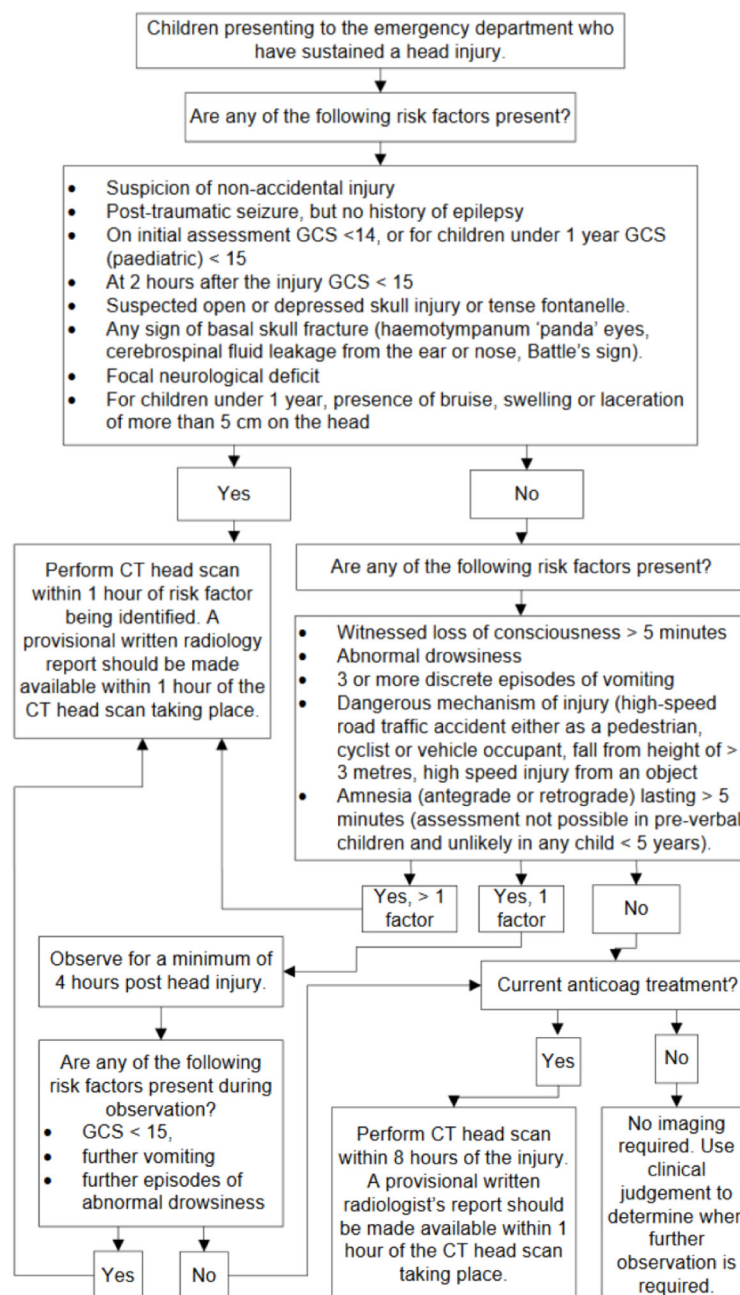
It would be prudent to review your department/region's guidance on managing children with head injuries, and make this available to your learners, or ask them to take a look before the session.

## Using guidance for CT imaging

CT imaging became the imaging modality of choice during the 2000s/2010s in developed economies. Since then, access to CT has generally widened, and become ubiquitous. Key to this in the UK has been the development of guidance by NICE, in 2014, with updates since - it guides management of head injury in children and adults. A trio of cohort studies looking at outcomes of children with head injury were key to the development of the paediatric part of this guideline - please see 'Key papers'. Included below is a flowchart guiding CT use in children courtesy of NICE.

**NICE** National Institute for Health and Care Excellence

**Algorithm 2: Selection of children for CT head scan**



## Key papers

### CHALICE (UK/2006)

highly sensitive but significantly less specific rule developed in the UK, later incorporated into the NICE guidance

### PECARN (US/2009)

cohort study looking to identify low-risk group of paediatric patients who could safely not be imaged

### CATCH (Canada/2010)

prospective multicentre cohort study from Canada looking to establish features for medium & high-risk for clinically significant traumatic brain injury

## CASE 1

A 6yo girl is brought in by ambulance to the ED you work in. She was playing on a climbing frame and fell off the top onto concrete, onto her head. Handover states that she was briefly knocked unconscious, then returned to a GCS = 15, but has become more drowsy en route to hospital.

On your initial assessment, there is a large swelling to the left side of her scalp and forehead, and there appears to be some blood leaking from her left ear. Her GCS is 12 (E3V4M5) but the rest of her vital signs are within normal limits.

### Outline your management steps

### How soon do you want this child to have CT imaging?

### The scan shows an extradural haematoma. How can you direct your team to prevent secondary brain injury?

## DISCUSSION POINTS

- This child needs immediate CT imaging of the head and their cervical spine - they are ideally managed by a trauma team, where the primary survey should ensure detection of any other injuries. If as likely, the cervical spine cannot be cleared clinically, they will need immobilisation until this is completed. A written report from an appropriate radiologist will ideally be available within 60mins of the scan.
- Significant CT findings (see 'Basics') will need urgent discussion with a neurosurgeon, to determine if the child needs emergency surgery. If not, a

clear management plan - who will monitor the child, and where? will need to be agreed.

- This child may require intubation, for airway, oxygenation & ventilatory control, or for secondary transfer. Tranexamic acid may be used. Attention should be paid to pain management, and neuroprotective initiatives should be put in place (control of ICP, blood pressure, CO<sub>2</sub>, O<sub>2</sub> & glucose - see the referenced paediatric FOAM article which provides a good summary of clinical management)

## CASE 2

You see a 20 month old boy in your ED, who was playing with his 6 year old cousin when he ran into an opening door at home. He cried immediately, and vomited around 10 minutes later.

Having been brought into the ED, which is 20 minutes from his home, he has vomited twice more. There was no LOC or seizure activity, and other than looking nauseated he appears to be behaving normally.

**To scan or not to scan?**

**What guidance do the parents/nursing staff looking after this child in the ED need?**

**How long will you observe for, and what if the child vomits again?**

**Discussion points:**

**When is a temperature classed as a fever?**

- This child can probably be safely observed without immediate CT scanning - this management approach would be supported by NICE (see sections 1.4.9 and 1.4.10).
- This case will hopefully provoke discussion about what constitutes a 'vomit', and whether there are any other plausible causes of vomiting, other than the injury itself.
- Learners could discuss what local provision they have for more extended observation of a child.
- Discussion of provision of verbal + written advice would also be pertinent.

## ADVANCED SECTION

The learning points here are for more advanced practitioners and so may be inappropriately pitched for those less experienced.

### ADVANCED CASE 1

A 9 month old child presents after rolling off a bed onto the floor. You see a 7cm swelling on his occiput. In the trauma call, he is held in mum's arms and is crying. You are unsure over how to proceed - the child definitely needs CT imaging, but how should we ensure they keep still?

#### Discussion points

- Recap of CT guidance - "For children under 1 year, presence of bruise, swelling or laceration of more than 5 cm on the head"
- Options for CT sedation: benzodiazepines vs. diamorphine/opiates vs. ketamine vs. intubation & ventilation - given a significant CT finding is possible. This would be a good opportunity to mention the 2020 revisions to RCEM ketamine sedation guidance (with associated DFTB commentary)

### ADVANCED CASE 2

An 8 year old girl is brought in by her dad. She clashed heads with another player at basketball two days previously, and did not initially seek medical advice as she was 'fine'. She had to leave school early today because she had trouble seeing the board & teacher, and felt sick. There are no focal neurological findings but there is a bruise on the parietal part of the scalp on the right, and you cannot feel the scalp. **What do you do?**

#### Discussion points

- Need for detailed history-taking around the delay in presentation - actively look for any safeguarding concerns
- Should we have an altered threshold for CT imaging when presentation is delayed? This DFTB post is a useful summary of a paper relating to this cohort of patients - finding of a nonfrontal scalp haematoma or strong suspicion of a basal skull fracture were significantly associated with a clinically significant brain injury.



## ADVANCED CASE 3

A 15 year old girl re-attends 10 days after being knocked unconscious for 10-15 seconds while jumping for a header playing football. She passed a pitchside concussion test and continued to play, but was substituted after saying she felt dizzy, and was seen in an ED. A CT scan was performed - which showed no bleed, contusion or fracture.

She says she found it hard to concentrate on schoolwork for a week afterwards, but this is now normal. She wants to know exactly when she can go back to playing as she has an important match in 3 days. **What do you do?**

### Discussion points

- Concussion describes the symptoms & abnormal function experienced by patients after a head injury, without any evidence of macroscopic brain injury. Its management is commonly misunderstood and poorly explained to patients and carers.
- Management focuses on cognitive rest, avoidance of activities that trigger symptoms, and graduated return to cognitive activity & education.
- Return to sport should also be graduated, with trial of light activity, and avoidance of sport with a risk of head impact until the patient has been reviewed by a clinician.
- There is a significant risk of [secondary concussion](#) if sport/normal activity is returned to too soon after the initial injury
- Some excellent resources from
  - BMJ ([podcast & article](#) + [infographic](#))
  - [PedsCases podcast](#) (+ [transcript](#))
  - [PEMPlaybook podcast](#)

Current UK guidance recommends that people recovering from concussion should be reviewed/assessed by a doctor before beginning activities which risk exposure to head trauma. The doctor's role is to ensure the patient:

has returned to work or school

is symptom free

is following the  
"graduated return to  
sporting activity"  
as above

## SIMULATION OPTIONS

**Blocked VP shunt in infant (HETV)**

**Headache & drowsiness in child (Bristol)**

### MCQS

**1. You see a 4 year old with a head injury. All of the following are an indication for urgent CT imaging except:**

- A**  
GCS<14
- B**  
Sign of a basal skull fracture
- C**  
Focal neurology on examination
- D**  
Post-traumatic seizure
- E**  
Loss of consciousness for a few seconds

NICE guidelines mention all of the above as indications for immediate CT except for LoC - if brief this is not an indication. If more prolonged (>5min), this would mandate observation in the ED for at least 4h after the time of injury.

**2. In an intubated child with an extradural haematoma causing mass effect, the following are important considerations in managing intracranial pressure:**

- A**  
Managing untreated pain
- B**  
Using RR or tidal volume to control pCO<sub>2</sub>
- C**  
Keeping O<sub>2</sub> saturations 94-98%
- D**  
Keeping blood glucose tightly controlled between 4-8
- E**  
Removing any constrictive neck devices (tube ties, cervical collars etc)

Evidence for tight glycaemic control has been superseded by the risks associated with hypoglycaemia for the injured brain. Prevention of hyperglycaemia would be a more sensible aim. All of the other answers would minimise increases in intracranial pressure, including aiming for a low-normal pCO<sub>2</sub>.

### 3. When managing children with head injuries True or False ?

1

If the mechanism of injury is dangerous, the cervical spine should be CT imaged along with the head.

2

It is good practice to discuss management of delayed presentations with a senior before discharge

3

3 vomits in 10 mins constitutes separate 'episodes' of vomiting.

4

CT imaging is essential in those with haemophilia.

5

Intranasal diamorphine can be used to manage pain & keep a child still for scanning.

If the child's head is being imaged with CT, best practice would be to extend to the cervical spine if concern exists regarding injury. Teams should use judgement of the mechanism, presence of abnormal neurology and GCS to help make this decision).

Evidence would suggest that presentation >24h after a head injury is associated with more significant findings, thus the threshold for scanning may need to be altered.

Clinical judgement needs to be exercised with regard to vomiting. NICE refers to a vomit being a 'single discrete episode' but does not explicitly define timing. Our practice would suggest significant time for recovery should be allowed between episodes eg. 20mins.

Diamorphine is a good analgesic for young children and its sedative effects can be harnessed when attempting to safely CT in mild agitation - although other options are more safe if airway protection is required.

Congenital bleeding diatheses such as haemophilia require a lower threshold for imaging, and would need urgent supplementation of clotting factors - but very minor trauma to the head may still be managed without CT.

## Take home tips

- 1 Observation costs nothing
- 2 Mechanism is everything
- 3 Sedation is likely to be a consideration in scanning young children - anticipate this
- 4 Use decision-support tools to guide your imaging & think carefully if presentation is delayed
- 5 Think NAI especially if an explanation for an injury does not hold up to repeated history-taking
- 6 When preventing secondary brain injury, think about physiology + optimising each aspect

## REFERENCES

 [fellows@dontforgetthebubbles.com](mailto:fellows@dontforgetthebubbles.com)