



**DFTB COVID-19
EVIDENCE REVIEW
10TH APRIL 2020**



TABLE OF CONTENTS

10

Introduction



In order to help facilitate the best possible care for children with COVID-19, we sought to aggregate and rapidly review all of the original research being produced pertinent to children, making it available to everyone. Speed has been essential, and in order to keep pace with the rapid production of new evidence, we have proceeded with informal, rapid, evidence synthesis. There have been a handful of studies which were obtained and deemed not suitable for inclusion, due to poor quality or patient overlap. A list of studies not included is available.

Our evidence summaries have undergone internal peer review, as well as being open to external review from our readers. We would like to highlight that due to the speed with which the evidence has been produced, much is of low quality. Many studies include few patients. There are 3 other significant issues:

1. Heterogeneous denominators. There is a significant amount of heterogeneity in the way cohorts or cases have been collected, and many of these are not directly comparable.
2. Overlap. Much of the current evidence has come from a few regions in China. We have tried to identify where cases series were at risk of including the same patients multiple times, but this remains a risk.
3. Non-peer reviewed evidence. Many included papers have come from pre-print servers. Whilst they appear of sufficient quality to be useful, they require caution when interpreting.

We hope this evidence review proves useful in helping manage children with COVID-19

Contributors: The project was coordinated by Alasdair Munro. Reviews were conducted by Alasdair Munro, Alison Boast, Henry Goldstein, Dani Hall, and Grace Leo. Digital/technical support was provided by Tessa Davis.



Executive summary of evidence

Epidemiology

Following the initial epidemiological data released from China, it appeared children were significantly less affected by infection with SARS-CoV-2 than their adult counterparts. This was reflected both in total case numbers, but also severity, with very few cases in young children and no deaths in children under 10yrs in the initial report. This finding has been reproduced in subsequent data from other countries, most notably Italy, which showed much lower rates of infection in children and no deaths in those under 30 years of age. Low numbers of childhood cases have been seen in the rest of Europe, as well as the USA, where 1/3 of childhood cases are in late adolescence. Some concerns exist that low case rates reflect selective testing of only the most unwell, however data from South Korea which has undertaken widespread community testing has also demonstrated significantly lower case numbers in children.

More detailed information has emerged from China into childhood severity of COVID-19. A large number of children appear asymptomatic. Critical illness was very rare (0.6%) and concentrated in the youngest infants. It should be noted that large numbers of “suspected” cases in this group leave room for a significant number of illnesses to have been caused by other, familiar respiratory viruses. In the USA CDC data, infants appear most likely to be hospitalised, although rates of PICU admission do not appear to be significantly different as yet.

To date, deaths remain extremely rare in children from COVID-19, with only a handful of reported cases.

Number of studies
included in this
report

46

To date, deaths remain extremely rare in children from COVID-19, with only a handful of cases reported.

Transmission

Precise details regarding paediatric transmission remain unclear. Low case numbers in children suggest a more limited role than was initially feared. Contact tracing data from Shenzhen in China demonstrated an equivalent attack rate in children as adults, however this has been contradicted by subsequent data in Japan which showed a significantly lower attack rate in children. This, coupled with low case numbers would suggest at least that children are less likely to acquire the disease. The role of children in passing the disease to others is unknown, in particular given large numbers of asymptomatic cases. Notably, the China/WHO joint commission could not recall episodes during contact tracing where transmission occurred from a child to an adult. A recent modelling study from the London School of Hygiene and Tropical Medicine (pre-print, not peer reviewed) however has suggested the most plausible explanation for low case rates was that children are more likely to be asymptomatic, rather than less likely to acquire the disease. Studies of family clusters have revealed children were unlikely to be the index case.

Several studies have now shown that SARS-CoV-2 can be detected by PCR in the stool of affected infants for several weeks after symptoms have resolved. This has raised the possibility of faecal-oral transmission. Research from Germany failed to find any live, culturable virus in stool despite viral RNA being detectable, suggesting this represents viral debris rather than active virus. Further studies will be needed to shed further light on this.

Clinical Features


A significant proportion of children with COVID-19 do not appear to develop any symptom, or have subclinical symptoms. In the absence of widespread community or serological testing, it is uncertain what this proportion is. The most detailed paediatric population data from China showed 13% of confirmed cases had no symptoms (cases detected by contact tracing). Considering both confirmed and suspected cases, 32% of children aged 6-10yrs were asymptomatic.

Clinical features in symptomatic children are somewhat different to adults. Children tend to have more mild illness. The most common presenting features are cough and fever, occurring in over half of symptomatic patients. Upper respiratory tract symptoms such as rhinorrhoea and sore throat are also relatively common, occurring in 30-40% of patients. It is not uncommon for children to have diarrhoea and/or vomiting (around 10% of cases), even in some cases as their sole presenting features.

Blood tests also show slightly different features to adults. Lymphocytopenia is relatively rare in children, with the majority having normal or sometimes raised lymphocyte counts. Inflammatory markers such as CRP and Procalcitonin are often raised but only very mildly. Slight elevations in liver transaminases appears common.

Radiographic features in children are also somewhat different to their adult counterparts. Chest X-rays are often normal, and many CT chest scans are also normal. When present abnormalities are often less severe, however a reasonable number of children have bilateral pneumonia. Changes may be found on CT even in asymptomatic children. Common features in abnormal CT scans include mild, bilateral ground glass opacities, but with less peripheral predominance than is reportedly found in adults.

There appears to be little in the way of clinical signs in children to differentiate COVID-19 from other childhood respiratory virus infections.



Newborns

A number of case reports have been published looking at the outcomes of pregnant mothers with COVID-19 and their newborn babies, with nearly 50 cases of infants now reported. Mothers and their babies in general appear to do well. As yet, cord blood, amniotic fluid and placental swabs persistently testing negative for SARS-CoV-2. There has been a few cases of infants delivered to mothers with COVID-19, who had elevated SARS-CoV-2 IgM. This may indicate intrauterine transmission, however swab PCR from these children has been negative and false positives with IgM tests are not uncommon. The vast majority of newborns have not acquired COVID-19 themselves. There have been case reports of newborns and very young infants testing positive (one at 36hrs of age) however they have not suffered any complications of the disease and required minimal respiratory support. One case series has described 10 infants delivered prematurely via emergency caesarean section who had a more difficult neonatal course, including one death with disseminated intravascular coagulation. All of these infants tested negative for SARS-CoV-2, and the reason for their premature delivery is unclear from the report.

Children With Comorbidities

There is little clinical data to inform us on the effect of COVID-19 on children with other comorbidities. Some data has been published from a liver transplant unit in Lombardy, Italy, which had 3 cases of COVID-19 in post-transplant patients who all suffered very mild symptoms. A case series of 9 children with inflammatory bowel disease on immunosuppression all suffered a mild course, as did a series of 5 children being treated for malignancy. Of note, in USA CDC data a high proportion of cases needing admission had at least 1 co-morbidity (most commonly respiratory)

Conclusion

COVID-19 appears to affect children less often, and with less severity, including frequent asymptomatic or subclinical infection. There is evidence of critical illness, but it is rare. The role of children in transmission is unclear, but it seems likely they do not play a significant role. Changes in laboratory or radiographic parameters are slightly different to adults, and changes usually mild. There is no direct evidence of vertical transmission, and early evidence suggests both infected mothers and infants are no more severely affected than other groups. Early evidence suggests no significant increased risk for children with immunosuppression, but further data is needed.

Table of evidence

FIRST AUTHOR JOURNAL

DATE OF PUBL.

COUNTRY

REGION


N# CHILDREN

STUDY TYPE

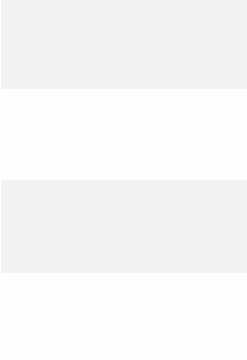
PAPER LINK


Press the tabs below to read the detailed summary in the document or press See paper to check the external link

Neonatal



Clinical





List of summary reviews



Dong et al (Neonatal)

Dong L, Tian J, Songming H et al. Possible Vertical Transmission of SARS-CoV-2 From an Infected Mother to Her Newborn. JAMA. Published online March 26, 2020. doi:10.1001/jama.2020.4621

This is a case report that would suggest that vertical transmission of COVID-19 can occur. A 34+2 primiparous woman was diagnosed with COVID-19 (she was symptomatic with fever and respiratory difficulty and had classic CT chest findings and a positive nasopharyngeal swab for SARS-CoV-2). She was treated with antiviral medications, antibiotics and corticosteroids.

Her female infant was delivered by caesarean section 4 weeks after the onset of her mother's symptoms in good condition with Apgars of 9 and 10. Although the infant's nasopharyngeal swabs were negative, her IgM antibodies against SARS-CoV-2 were raised at 2 hours post delivery and cytokine levels were elevated. The risk of environmental infection was minimised: the caesarean was performed in a negative pressure room, the mother wore an N95 mask and did not hold her infant and the infant was immediately isolated in NICU. Maternal vaginal secretions were negative for SARS-CoV-2, which would also suggest the infection did not happen at birth. As IgM antibodies do not cross the placenta, the infant's elevated IgM antibody levels suggest that she was infected in utero. Moreover, IgM antibodies usually do not appear until 3 to 7 days after infection. The infant also had raised IgG antibodies, but IgG is transferred placentally so this may reflect maternal or infant infection. The mother's breast milk was negative for SARS-CoV-2 1 week following delivery.

Zeng et al (Neonatal)

Zeng L, Xia S, Yuan W et al. Neonatal Early-Onset Infection With SARS-CoV-2 in 33 Neonates Born to Mothers With COVID-19 in Wuhan, China. JAMA Pediatrics. Published online March 26, 2020. doi:10.1001/jamapediatrics.2020.0878

This is a cohort study following 33 neonates born to COVID-19 positive mothers, recruited Wuhan Children's Hospital, Hubei Province, China, between January 2020 and February 2020. The authors describe three cases of early-onset neonatal COVID-19, which they suggest implies vertical transmission. However, amniotic fluid, cord blood and maternal breast milk of the mothers of all 3 positive neonates were negative for SARS-CoV-2, therefore it is unclear whether the infection was transmitted vertically or environmentally.

Three of the 33 neonates tested positive for COVID-19 on day 2 of life (positive nasopharyngeal or anal swabs). All 3 were born by caesarean section, two at term and the third at 31+2 for premature rupture of membranes and foetal distress.

Clinical features: The two term COVID-19 positive neonates had fever, although the authors don't define what temperature they consider fever. These two neonates were also lethargic, but neither had respiratory distress. Neonate 3 was the most unwell, although this may be due to prematurity, poor condition at birth and sepsis rather than COVID-19. He was born at 31+2, required resuscitation at birth and had poor Apgars of 3, 4 and 5 at 1, 5 and 10 minutes, requiring non-invasive ventilation for respiratory distress. His blood cultures were positive for *Enterobacter agglomerates*.

Bloods: Neonate 1 (fever and lethargy) had normal bloods except raised procalcitonin (0.09 microgram/L). Neonate 2 (fever, lethargy and vomiting) had a leucocytosis, lymphocytopenia and elevated CK. Neonate 3 (premature with sepsis) had leucocytosis, thrombocytopenia and coagulopathy with prolonged PT (21 sec) and APTT (81.9 sec).

Radiology: All 3 had radiological evidence of pneumonia on CXR.

The authors state that because strict infection control and infection prevention procedures were implemented during delivery, SARS-CoV-2 isolated from their upper respiratory tracts or anuses was therefore maternal in origin. However, although it is stated in the illustration that one neonate was immediately quarantined after birth, it's not clear whether this was the case for the other two babies. Plus, the negative amniotic fluid and cord blood does raise the question as to whether these neonates were truly infected in utero or not.

Zeng et al (Neonatal)

Zeng H, Xu C, Fan J, et al. Antibodies in Infants Born to Mothers With COVID-19 Pneumonia. JAMA. Published online March 26, 2020. doi:10.1001/jama.2020.4861

This report outlines the course of 6 mothers who were symptomatic for COVID-19 in their last trimester, and gave birth to 6 liveborn infants. This study is notable for antibody testing of both mothers and infants. The accuracy of the antibody tests are suspiciously high given current struggles to produce adequate tests around the world, and should be treated with a high degree of caution.

All 6 infants were born in good condition, and all tested negative for SARS-CoV-2 viral throat swabs and blood PCR. Unsurprisingly all infants had elevated IgG or SARS-CoV-2 (as this crosses the placenta), but notably 2 infants had raised IgM (39.9AU/ml and 16.25AU/ml). This raises the possibility of intrauterine infection, similar to another case of an infant with raised IgM (Dong et al JAMA). Issues with cross reactivity of IgM are well described, and so whilst full validation of these tests is awaited internationally, this should be treated with caution.



Yu et al (Neonatal)

Yu, Nan et al. Clinical features and obstetric and neonatal outcomes of pregnant patients with COVID-19 in Wuhan, China: a retrospective, single-centre, descriptive study, The Lancet Infectious Diseases, Volume 0, Issue 0, Published: March 24, 2020 DOI: [https://doi.org/10.1016/S1473-3099\(20\)30176-6](https://doi.org/10.1016/S1473-3099(20)30176-6)

This is a retrospective study of 7 pregnant mothers infected with COVID-19 between Jan 1st and Feb 8th at Tongji Hospital in Wuhan, China. They were all at term (range 37/40 – 41+2/40). The mothers were all symptomatic, mainly with fever, cough, shortness of breath and diarrhoea. They all delivered via emergency caesarian section. All mothers did well.

The babies were all born with normal apgars. 4 babies were discharged home and not tested for SARS-CoV-2 and never developed symptoms (including at 28d follow up phone call. 3 children were tested, of which one was positive at age 36hrs (reported in separate study, Wang et.al Clinical infectious Diseases, but did well with no fever or cough and mild shortness of breath). The other 2 tested negative and were later discharged without complication.

Fan et al (Neonatal)

Fan C, Lei D, Fang C, et al. Perinatal Transmission of COVID-19 Associated SARS-CoV-2: Should We Worry? Clin Infect Dis Published Online First: 17 March 2020. doi:10.1093/cid/ciaa226

This is a case series of two women (both physicians) infected with SARS-CoV-2 during the third trimester in late January, Wuhan China. They gained consent to collect swabs from the mother, specimens of maternal serum, cord blood, placental tissue, amniotic fluid, vaginal swab and breast milk. All the above tested negative for SARS-CoV-2 by PCR

The first neonate was isolated immediately following delivery via caesarean section, and no swabs were positive for SARS-CoV-2. The baby was treated for lung infection on day 3 due to low grade fever and “diffuse haziness” on both lung fields with lymphopaenia.

The second neonate was also delivered via caesarean section and reportedly developed mild neonatal pneumonia and lymphopaenia, treated again with antibiotics (no indication of time course). Similarly there was no evidence of vertical transmission with all products of conception testing negative, as did the infant. There were no maternal complications in either case.

This paper provides further reassurance that there is no evidence of vertical transmission, and of a relatively mild disease course for mothers. In the event of both children being treated for pneumonia but testing negative, it is hard to know if this was understandable overcautiousness or true infection. In either case, the infants did well.





Chen et al (Neonatal)

Chen Y, Peng H, Wang L, et al. Infants Born to Mothers With a New Coronavirus (COVID-19). Front Pediatr 2020;8:104. doi:10.3389/fped.2020.00104

This is a case series of 4 mothers symptomatic with COVID-19 in Wuhan. All babies were born after 37/40 with reasonable APGARS. All babies were then isolated from their mothers and formula-fed. All tested negative for SARS-CoV-2. Two babies had a rash (which sound very much like normal newborn rashes) and one had transient tachypnoea of the newborn, briefly requiring CPAP and made a full recovery. There was no evidence of vertical transmission.

Li et al (Neonatal)

Li N, Han L, et al. Maternal and neonatal outcomes of pregnant women with COVID-19 pneumonia: a case-control study. doi:10.1101/2020.03.10.20033605
A pre-print, the information should be treated with caution until it has undergone peer review.

This was a case-control study (Jan 24 – Feb 29) in Wuhan, China
16 women with confirmed COVID-19 pneumonia and 18 suspected cases (typical CT chest findings but PCR negative) were used as cases, and 121 women randomly selected from the same period were selected as controls, and a further were 121 selected from 2019 as controls to avoid the impact of mental stress from lockdown.

Complications in mother were found in 70% in COVID19 cases – much higher than in controls. We will mainly focus on infants. 17 babies were delivered to the 16 mothers (15 singletons, one set of twins) with confirmed COVID-19. Preterm delivery was higher in the cases, with 23.5% of confirmed COVID19 mothers birthing prematurely compared to 5% of controls. However, mean gestation was still 38+2 in the cases.

There was no difference in APGAR scores, no cases of vertical transmission and no neonatal complications.





Wang et al (Neonatal)

Xiaotong Wang, Zhiqiang Zhou, Jianping Zhang, Fengfeng Zhu, Yongyan Tang, Xinghua Shen, A case of 2019 Novel Coronavirus in a pregnant woman with preterm delivery, Clinical Infectious Diseases, ciaa200, <https://doi.org/10.1093/cid/ciaa200>

This brief report outlines the case of a mother in Suzhou, China, who became symptomatic and tested positive for SARS-CoV-2 in sputum whilst 30/40 pregnant. She had recently travelled to Wuhan. She had an emergency caesarean performed 6 days after presentation for worsening clinical status and concerns for the foetus due to reduced movements and foetal heart rate variability on CTG.

The infant was born in good condition and immediately isolated from the mother. Samples of amniotic fluid, cord blood, placental swabs, infant gastric secretions and throat swabs all tested negative for SARS-CoV-2. Repeat swabs from the infant on day 3 of life were still negative. Mother and baby both recovered well with uneventful postpartum and neonatal course.

Wang et al (Neonatal)

Shaoshuai Wang, Lili Guo, Ling Chen, Weiyong Liu, Yong Cao, Jingyi Zhang, Ling Feng, A case report of neonatal COVID-19 infection in China, Clinical Infectious Diseases, ciaa225, <https://doi.org/10.1093/cid/ciaa225>

This brief report is of a mother who lived near the market in Wuhan which was the epicentre of the initial outbreak. She became febrile with vaginal bleeding at 40/40 gestation and CT showed signs of viral pneumonia. There were no fetal concerns. They proceeded to emergency caesarean section.

The infant was delivered in good condition, required no resuscitation, and was separated from the mother at birth. Bloods were performed which showed mild lymphopaenia ($2.43 \times 10^9/L$) and slightly elevated transaminases (AST 143 U/L) and CK (479 U/L). The baby was given IV penicillin (prophylaxis) and Vit K, and at 36hrs of age was swabbed for SARS-CoV-2, which later returned as positive. No supplemental oxygen was required, and no clinical evidence of infection demonstrated. CT chest of the baby demonstrated patchy shadowing bilaterally. Swabs of placenta and cord blood were subsequently tested for SARS-CoV-2 and returned negative.

Despite testing positive early in life for COVID-19, there remains no evidence of vertical transmission, and reassuringly the infant was completely asymptomatic.





Chen et al (Neonatal)

Chen Y, Peng H, Wang L, et al. Infants Born to Mothers With a New Coronavirus (COVID-19). Front Pediatr 2020;8:104. doi:10.3389/fped.2020.00104

This is a case series of 4 mothers symptomatic with COVID-19 in Wuhan. All babies were born after 37/40 with reasonable APGARS. All babies were then isolated from their mothers and formula-fed. All tested negative for SARS-CoV-2. Two babies had a rash (which sound very much like normal newborn rashes) and one had transient tachypnoea of the newborn, briefly requiring CPAP and made a full recovery. There was no evidence of vertical transmission.

Zhu et al (Neonatal)

Zhu H, Wang L, Fang C, et al. *Clinical analysis of 10 neonates born to mothers with 2019-nCoV pneumonia. Transl Pediatr* 2020;9:51–60. doi:10.21037/tp.2020.02.06

This is a retrospective series of 10 neonates (including a set of twins) born to 9 mothers in Hubei province who were confirmed to have COVID-19.

4 mothers had symptoms prior to delivery, 2 mothers on the day of delivery, and 3 mothers after delivery. 7 mothers delivered via caesarean section and 2 by vaginal delivery. There was intrauterine distress recorded in 6 cases.

Of the babies, 8 were male and 2 female, 4 born at term and 6 preterm (twins at 31/40, and 4 babies around 34 – 35/40). APGARS were good for all babies. 6/10 developed some respiratory symptoms, one had some vomiting and one developed shock with DIC and multiple organ failure, who later passed away. All neonates tested negative for SARS-CoV-2, as did placental swabs.

It is hard to know what to make of this study. There is little information about how/why babies were delivered prematurely, and it would seem most symptoms are related to their early arrival. None were positive for the virus, and there was no evidence of vertical transmission. It seems contradictory to other evidence of babies delivered to mothers with COVID-19 who did well. Interpret with great caution.





Balduzzi et al (Clinical)

Balduzzi, A, Brivio, E, and Rovelli, A et al, Lessons After the Early Management of the COVID-19 Outbreak in a Pediatric Transplant and Hemato-Oncology Center Embedded within a COVID-19 Dedicated Hospital in Lombardia, Italy. Estote Parati. (Be Ready.) (3/19/2020). Available at SSRN: <https://ssrn.com/abstract=3559560> or <http://dx.doi.org/10.2139/ssrn.3559560>

This report from a paediatric haematology unit in Lombardia, Italy, includes the Italian experience of COVID-19 in children with malignancy so far. At their particular unit, they have had no children with malignancy test positive for COVID-19 (they admit this is dependent on testing criteria, requiring hospitalisation at their institute). They are aware of 5 cases of paediatric cancer patients who have had COVID-19 and have all suffered a mild course, with 3 managed at home and 2 in hospital.

This small case series provides further reassurance for at risk paediatric populations.



Kamali Aghdam et al (Clinical)

Kamali Aghdam M, Jafari N, Eftekhari K. Novel coronavirus in a 15-day-old neonate with clinical signs of sepsis, a case report [published online ahead of print, 2020 Apr 1]. *Infect Dis (Lond)*. 2020;1–3. doi:10.1080/23744235.2020.1747634 Accessed from: <https://www.tandfonline.com/doi/full/10.1080/23744235.2020.1747634> on 4th April

This brief case report from Iran is of a 15 day old male from Mousavi Hospital in Zanjan, Iran. Date of admission was not available. Symptoms were fever and lethargy with his parents having fever and cough. He initially appeared tachycardic and febrile with sats of 93% on RA. He was given Vancomycin, Amikacin and Oseltamivir. SARS-CoV-2 was detected on RT-PCR. His parents were not tested as they did not meet the testing criteria at the time (hospitalisation).

Radiology: Chest X-ray had nil findings

Bloods: WCC 6.7, Lymphocytes 36%, Neutrophils 42% and CRP 1 (normal).

Comorbidities: There was an incidental finding of patent foramen ovale on Echo.

Outcome: He had improvement by day 2 of admission and was cleared for discharge on day 6.

Su et al (Clinical)

Su L, Ma X, Yu H, et al. The different clinical characteristics of coronavirus disease cases between children and their families in China – the character of children with COVID-19. Emerg Microbes Infect. 2020;9(1):707–713. doi:10.1080/22221751.2020.1744483

This study from the Jinan Infectious Disease Hospital retrospectively reviewed cases of nucleic acid-positive SARS-CoV-2 patients between 24th January to 24th February 2020 (detected using the (ORFlab/N) nucleic acid detection kit by Bio-germ, Shanghai, China). Nine children and members of their family totalling 14 adults were included. Note that two family members missed enrollment as they were at another hospital. Of the 9 children, 6 were female (66%). The age group ranged from 11 months to 9 years and 9 months old (mean age 4.5 years). For eight of the nine children, there was history of their parents having travelled frequently, being in contact with someone from Wuhan or having worked or visited Wuhan. Of note, five of the discharged children were readmitted to hospital because their stool showed positive results in SARS-CoV-2 PCR.

Clinical Features (children): 3 of the 9 children had fever (33%) and one had cough (11.2%). Imaging (children): On chest x-ray and CT, two children had findings consistent with bronchitis (22.2%), one had bronchial pneumonia (11.1%) and a further one had pulmonary consolidation and ground glass opacity. From the two example images included,, findings appear to be bilateral but this was not specified in the body of the text. Bloods (children): 8 of 9 children (88.9%) had normal or decreased white blood cell counts. Six children (66.7%) had increased CK-MB. ALT, AST. All children had a normal CRP, PCT, ESR and IL-6. Clinical Features (adults): Of the 14 adults, 8 (57.1%) had fever, five had cough (35.7%), three had chest tightness or pain (21.4%), a further three had fatigue (21.4%) and one reported a sore throat (7.1%). Imaging (adults): Ten (71.4%) had abnormal imaging mainly pulmonary consolidation, with 7 (50%) having nodular shadow and 7 (50%) having ground glass opacities. Bloods (adults): Four (28.6%) had reduced white cell count with seven (50%) having lymphocytopenia.



Turner et al (Clinical)

Turner D, Huang Y, Mart n-de-Carpi J, et al. COVID-19 and Paediatric Inflammatory Bowel Diseases: Global Experience and Provisional Guidance (March 2020) from the Paediatric IBD Porto group of ESPGHAN [published online ahead of print, 2020 Mar 31]. J Pediatr Gastroenterol Nutr. 2020; doi:10.1097/MPG.0000000000002729


This article outlines the experience from Asia and Europe so far of children with inflammatory bowel disease given the COVID-19 pandemic. This is of particular interest because many of these children receive immunosuppression as part of their treatment, and so could be considered high risk for complications of the disease.

It appears to have been routine practice to suspend treatment for IBD during the outbreak of COVID-19, which resulted in a large number of relapses. No children with IBD contracted COVID-19 in China in the period covered by the survey.

In South Korea treatment for IBD was not suspended. They also have had no cases of COVID-19 in children with IBD.

In the PORTO IBD group of ESPGHAN (covering Europe, some centres in Canada and Israel) treatment was not suspended in 31/32 centres. 7 children with IBD, who were on immunosuppression, had COVID-19. They all suffered a mild illness with no flare of their IBD. There is an additional child case from an international IBD database identified who also experiences mild symptoms (no hospitalisation required).

This survey provides further reassurance that treatment with immunosuppression does not appear to significantly increase the risk of severe disease from COVID-19 in children.





Qui et al (Clinical)

Qiu, Haiyan et al, Clinical and epidemiological features of 36 children with coronavirus disease 2019 (COVID-19) in Zhejiang, China: an observational cohort study. The Lancet Infectious Diseases, Volume 0, Issue 0 DOI:[https://doi.org/10.1016/S1473-3099\(20\)30198-5](https://doi.org/10.1016/S1473-3099(20)30198-5)

Qui and colleagues retrospectively identified 36 children with an EMR diagnosis of COVID-19, during the period Jan 17 through March 1st, at three hospitals in Zhejiang, China, a province 900km to the east of Wuhan. Diagnosis was made by COVID-19 RT PCR for all patients presenting with fever, cough and radiographic presentation, or if there was a history of exposure to an infected individual.

For the mild cohort, 28% of patients were asymptomatic, with moderate cases more likely to have fever of 38°C or higher (47%), cough (24%), vomiting or diarrhoea (10%) or headache (10%). More than half (53%) of patients had ground-glass opacities on CT scan, meeting the case definition for Moderate illness. Key laboratory values of note include lymphopaenia, leucocytopenia and increased procalcitonin as all associated with moderate illness. No patients in this cohort were hypoxaemic as a result of their pneumonia.

The authors also draw comparisons between adults and children with COVID-19 (less severe illness, less likely to have abnormal investigations), as well as comparing the clinical features and severity of COVID-19 with SARS (milder symptoms and severity) and H1N1 influenza (fewer symptoms, more frequent pneumonia) in children. Wisely, Qui & colleagues note the high rate of findings that are not clinically obvious, and the high proportion of asymptomatic cases make for very challenging case identification in the absence of clear epidemiologic information. “This finding suggests a dangerous situation if community-acquired infections occur.”

Zheng et al (Clinical)

Zheng F, Liao C, Fan Q-H, et al. *Clinical Characteristics of Children with Coronavirus Disease 2019 in Hubei, China. Curr Med Sci 2020;:1–6. doi:10.1007/s11596-020-2172-6*


This is a retrospective case series of 25 children <14 years of age hospitalised with COVID-19 from 10 hospitals across the Hubei province between February 1st and February 10th 2020. It is unclear how the cases were ascertained. 14/25 were male (54%) and the median age was 3yrs (IQR 2-9yrs). Most patients were <3 years (40%). 2 patients had a background of repaired congenital heart disease (both infants), although we have no more detail than this. Both of these children went on to develop critical illness.

Clinical features: 13/25 (52%) had fever, 11/25 (44%) had cough, 3/25 (12%) had diarrhoea, and 2/25 (8%) had nasal congestion, vomiting, breathlessness or abdominal pain.

Bloods: Inflammatory markers were not particularly raised, with a median CRP of 14.5mg/L (IQR 0.93 - 25). 10/25 (40%) patients had lymphopenia.

Radiology: CT chest was normal in 8/24 (32%) with unilateral involvement in 5/24 (20%) and bilateral in 12/24 (48%). Changes typically showed patchy shadows. Younger children appeared more likely to have bilateral lung findings than older children.

Co-infection: Other organisms identified included *Mycoplasma pneumoniae* (3/25, 12%), Influenza B (2/25, 8%) and one of the 2 critically ill children had *Enterobacter aerogenes*.





Lou et al (Clinical)

Lou XX, Shi CX, Zhou CC, et al. Three children who recovered from novel coronavirus 2019 pneumonia. J Paediatr Child Health Published Online First: 22 March 2020. doi:10.1111/jpc.14871

This is a case series of 3 children diagnosed with COVID-19 and admitted in the Zhengzhou University Children's hospital in Henan Province, China (dates not provided). They were 2 sisters aged 6 and 8yrs, and a 6m old infant. The children were all infected by a family member, although the family of the 6m infant had no link to Wuhan.

Clinical features: All 3 had a fever, 2 had nasal congestion and rhinitis alongside fatigue, diarrhoea, and headache. The 6yr old girl had a cough.

Radiology: All 3 patients had CT scans with bilateral infiltrates

Bloods: Not reported

Outcomes: No children required intensive care/intubation or had any severe complications. All have been discharged. The 2 sisters were treated with nebulized interferon.

Liu et al (Clinical)

Liu H, Liu F, Li J, Zhang T, Wang D, Lan W. Clinical and CT Imaging Features of the COVID-19 Pneumonia: Focus on Pregnant Women and Children [published online ahead of print, 2020 Mar 11]. J Infect. 2020;S0163-4453(20)30118-3. doi:10.1016/j.jinf.2020.03.007

This study is a review of CT imaging findings in children and pregnant women in a hospital in the Hubei Province. Four children with confirmed COVID-19 infection were included in the study. The bottom line is that pulmonary CT changes in children were mild, with either focal ground glass opacification or focal consolidation. Although CT has been reported as a useful screening tool in adults with suspected COVID-19 infection, the CT changes of the four children were non-specific; the authors conclude that exposure history and clinical symptoms are more helpful for screening in swab-negative children than CT. 41 pregnant women with either laboratory-confirmed or clinically-diagnosed COVID-19 infection were included in the study. All pregnant women had mild courses of their COVID-19 illnesses. Six of the 16 laboratory-confirmed pregnant women and 10 of the 25 clinically diagnosed pregnant women delivered during the study period. There were no cases of vertically transmitted COVID-19 in the neonates born to these pregnant women.

Case 1: 5 year old female with fever, cough and fatigue. No lymphadenopathy. Bloods: low WCC with raised lymphocytes and decreased neutrophil ratio. Normal CRP. CT: normal. Follow-up CT 9 days later remained normal.

Case 2: 11 month old male with fever and cough. No lymphadenopathy. Bloods: normal WCC with raised lymphocyte count and decreased neutrophil ratio. Normal CRP. CT chest: single consolidation without peripheral predominance (unlike reported findings in adults).

Case 3: 9 year old female with fever but no cough. No lymphadenopathy. Bloods: normal WCC, low lymphocytes and normal neutrophil ratio. Normal CRP. CT chest: single ground glass opacity without peripheral predominance (unlike reported findings in adults).

Case 4: 2 month old male with cough but no fever. No lymphadenopathy. This infant was coinfecting with RSV. Bloods: normal WCC with normal lymphocytes and normal neutrophil ratio. CRP raised (does not say how high). CT chest: multiple focal consolidations and pleural effusion. This infant's CT findings were more severe than the other three children, thought to be due to coinfection with RSV.



D'Antiga et al (Clinical)

D'Antiga L. (2020), Coronaviruses and immunosuppressed patients. The facts during the third epidemic. Liver Transpl. Accepted Author Manuscript. doi:10.1002/lt.25756

This letter is from a liver transplant centre in Lombardy, Italy, reporting their experience of patients (including children) with immunosuppression and COVID-19. They have had 3 children post liver transplant test positive for SARS-CoV-2, and none have developed clinical pulmonary disease. They believe due to the widespread nature of infection that many other of their patients may also be infected, but not developed clinically apparent disease.

This provides the first official reports of vulnerable paediatric populations with COVID-19, which so far does not appear to be any more severe than the rest of the population in that age bracket. Further data is awaited.

Lu et al (Clinical)

Lu X, Zhang L, Du H, et al. SARS-CoV-2 Infection in Children. *N Engl J Med* 2020;:NEJMc2005073. doi:10.1056/NEJMc2005073

This retrospective study examines the clinical characteristics of children with confirmed COVID-19 diagnosed at Wuhan Children's hospital. There were 1391 children tested between Jan 28th and Feb 26th 2020 due to known contact with a case of COVID-19, of these 171 were confirmed to have SARS-CoV-2. Median age was 6.7yrs, and there was a relatively even spread amongst age groups. Children were predominantly male (104/171, 60.8%).

Clinical features: 83/171 had cough, 79/171 had pharyngeal inflammation (sore throat), 71/171 had fever. 15/171 had diarrhoea and 13/171 had rhinorrhoea. 49/171 were tachypnoeic on admission and 72/171 were tachycardia. Only 4/171 had Oxygen saturations <92% during hospitalisation. 0/31 infants <1yr were asymptomatic in this cohort, with rates of asymptomatic infection increasing with age. There were higher rates of pneumonia in infants (25/6), but the definition of this is unclear. We also have no information regarding co-infection with other viruses or bacteria.

Radiology: Not delineated into CXR or CT, but descriptions sound like CT findings. The most common was bilateral ground glass opacity (56/171) followed by unilateral patchy shadowing (32/171) and bilateral patchy shadowing (21/171). There were several children with radiographic pneumonia who were asymptomatic.

Bloods: The supplementary appendix contains lab results. Only 6/171 patients had lymphopaenia, the vast majority were in normal range (Med $2.9 \times 10^9/L$, IQR 2.2 – 4.4). CRP was elevated (>10mg/L) in 33/171 (Med 4, IQR 1.3 – 8) of which 27/33 had pneumonia.

Outcomes: 3 patients required ITU admission and intubation. All 3 had comorbidities, including hydronephrosis, leukaemia and intussusception. The child with intussusception suffered multiorgan failure and died after 4 weeks. The cause of death is not clear from the report. As of writing 149 patients had been discharged with 21 stable in the general wards.





Cui et al (Clinical)

Cui Y, Tian M, Huang D, et al. A 55-Day-Old Female Infant infected with COVID 19: presenting with pneumonia, liver injury, and heart damage. J Infect Dis Published Online First: 17 March 2020. doi:10.1093/infdis/jiaa113

This is a case report of a 55 day old with SARS-CoV-2 who was admitted to hospital in China on February 2, 2020. She was treated with inhaled interferon-alpha-1b, amoxicillin, reduced glutathione, ursodeoxycholic acid, and traditional Chinese medicine lotus qingwen. The child was initially well, although her respiratory status worsened on day 2-6, and she required supplemental oxygen via nasal cannulae. Anal swabs on day 11 and 13 were positive on day 11-13 despite negative pharyngeal swabs.

Note is made in the title of this study that the infant sustained liver injury and heart damage. This is on the basis of marginally elevated liver transaminases and cardiac troponin measurements, for which it is unclear why the tests were performed. There is no indication of any clinical compromise demonstrated. It should be noted that a significant proportion of the child's care (including investigations) would not be considered standard practice in UK/US/Aus paediatric medicine.

Ji et al (Clinical)

Ji L, Chao S, Want Y et al. Clinical features of pediatric patients with COVID-19: a report of two family cluster cases. World J Pediatr. 2020 Mar 16. doi: 10.1007/s12519-020-00356-2. [Epub ahead of print] <https://dx.doi.org/10.1007/s12519-020-00356-2>

This is a review of two confirmed paediatric cases of COVID-19 (both from oropharyngeal swabs) from two family clusters with recent travel to Wuhan. One child presented with fever and the other with diarrhoea.

Case one: 15-year-old boy presenting with a one-day history of fever. Clinical features: Temperature 37.9°C, pharyngeal congestion. Normal lung auscultation. Laboratory findings: mildly elevated white cell count at $11.82 \times 10^9/L$, predominantly neutrophils (67.3%) and 25.7% lymphocytes. His CRP was mildly elevated at 35 mg/L. Radiological findings: normal unenhanced CT chest. Outcome: Symptomatic treatment. Symptoms disappeared after two days. Family information: both parents also tested positive for SARS-CoV2.

Case two: 9-year-old boy presented with mild diarrhoea but no cough and no fever. Normal examination. Laboratory findings: normal white cell count and normal CRP. Radiological findings: normal unenhanced CT chest. Outcome. Treated with oral probiotic and symptoms disappeared after 2 days. Family information: Family members had negative COVID-19 swabs but were symptomatic. His mother presented with fever and cough with bilateral peripheral ground glass opacifications on CT chest. The child's father and two-year old sister had normal CT chests but had mild symptoms consistent with COVID-19: his father had a cough for four days and his two-year-old sister had a transient two-day low-grade fever.





Zhang et al (Clinical)

Zhang C, Gu J, Chen Q, et al. Clinical Characteristics of 34 Children with Coronavirus Disease-2019 in the West of China: a Multiple-center Case Series. doi:10.1101/2020.03.12.20034686

A pre-print, the information should be treated with caution until it has undergone peer review.

This is a further retrospective case study looking at 34 children with confirmed COVID-19 between Jan 1st and Feb 25th 2020 in 4 hospitals in Western China. They were aged 1 month to 12 years.

Clinical features: The most common symptom was fever (26/34) followed by cough (20/34), followed by vomiting (4/34) and diarrhoea (4/34). A significant number had co-infections (16/34) including *Mycoplasma pneumoniae* (9/34), influenza A or B (12/34) and 2/34 were mononucleosis. One child had a nephroblastoma and one had asthma. The median incubation period was 10 days (IQR 7.75 – 25.25) and median 3 days (IQ 2 – 4) from admission to fever resolution

Bloods: Lymphocytosis was most common (17/34). CRP was not significantly elevated (median 7.56ml/L, IQR 1.21 – 15.13), but was >5 for 20/34, and procalcitonin was not significantly elevated either (0.6, 0.03 – 0.07)

Radiography: On chest CT 14/34 had patchy shadows bilaterally, 14/34 unilaterally, and 6 had normal CT chest.

Xing et al (Clinical)

Xing Y, Ni W, Wu Q, et al. Prolonged presence of SARS-CoV-2 in feces of pediatric patients during the convalescent phase. doi:10.1101/2020.03.11.20033159

A pre-print, the information should be treated again with caution until it has undergone peer review.

This study of 3 paediatric patients with COVID-19 from Qingdao, China (aged 1.5, 5 and 6 years) all had fevers and none were severe. All children had elevated lymphocytes ($>4.4 \times 10^9/L$) and 2 of 3 had abnormalities on chest CT (consolidation in one and ground glass changes in the other). The primary point made in the paper is that whilst respiratory swabs were negative within 2 weeks after children became afebrile, stool remained positive for over 4 weeks.





Xu et al (Clinical)

Xu, Y, Li X. Zhu, B. et al. Characteristics of pediatric SARS-CoV-2 infection and potential evidence for persistent fecal viral shedding. Nat Med (2020). <https://doi.org/10.1038/s41591-020-0817-4>

This study presents the results of widespread screening for COVID-19 in Guangzhou in China. 745 children were screened of which 10 were positive for COVID-19. Their ages ranged from 2 months to 15 years.

Clinical features: 6/10 had a fever over 38°C. 5/10 had a cough. 4/10 had a sore throat. 2/10 had rhinorrhoea and 2/10 had diarrhoea.

Radiography: 7/10 had coarse lung markings on CXR with no pneumonia, and 3/10 were normal. CT scans revealed ground glass or patchy opacities in 5/10.

Bloods: Basically normal in all cases

They made note that rectal swabs were frequently positive and that these swabs were positive for a longer duration than nasal swabs. The authors suggest on this basis that faecal-oral transmission may be possible, however this is very uncertain and will require further research to elucidate.

Liu et al (Clinical)

Liu W, Zhang Q, Chen J, et al. Detection of Covid-19 in Children in Early January 2020 in Wuhan, China. N Engl J Med 2020;;NEJMc2003717. doi:10.1056/NEJMc2003717

This letter to the editor describes a case series from Tongji hospital in Wuhan, China, taken from a cohort of 366 hospitalized children between January 7th and 15th 2020. 6 children were PCR Positive for COVID-19. Of the 6 patients, age range 1-7 years. All had fever $>39^{\circ}\text{C}$, cough and 4/6 had vomiting. All had lymphocytopenia, with 4/6 leukopenia and 3/6 with neutropenia. One child required an ICU admission, receiving pooled donor IVIG. The median recovery time was 7.5 days. Authors surmise COVID-19 occurs in children with some moderate-severe episodes of illness.





Li et al (Clinical)

*Li W, Cui H, Li K, Fang Y, Li S. Chest computed tomography in children with COVID-19 respiratory infection [published online ahead of print, 2020 Mar 11]. *Pediatr Radiol.* 2020;10.1007/s00247-020-04656-7. doi:10.1007/s00247-020-04656-7*

This study describes five children with confirmed COVID-19 who had CT chest scans in a large tertiary level hospital in China. Three of the five children had patchy ground-glass opacities on their CT scans but these changes were less severe than those seen in infected adults. The treatment is not detailed in the paper, so presented as published in this summary.

Case 1: 17 month old asymptomatic male. Bloods: CRP 9.4, WCC 9.2. Radiology: CT chest performed on day 4 showed patchy ground glass opacities. Repeat CT on day 9 after treatment had normalised (antiviral, anti-infective, immunoglobulin, interferon and Lianhua qingwen granules). No CXR.

Case 2: 10 month old asymptomatic female. Bloods: CRP 0.9, WCC 14.8. Radiology: Day 2 scan: normal. Not repeated. No CXR.

Case 3: 3 year old male with coryza, productive cough, sore throat and fever after 3 days. Bloods: CRP 0.7, WCC 15.0. Radiology: Day 9 CT showed patchy ground-glass opacities. Repeat CT on day 16 had normalised after treatment (antiviral, anti-infective, immunoglobulin). No CXR.

Case 4: 4 year old asymptomatic male. Bloods: CRP 0.2, WCC 6.6. Radiology: Day 2 CT chest showed patchy ground-glass opacities. Repeat CT on day 7 had normalised after treatment (montelukast, immunoglobulin). No CXR.

Case 5: 6 year old asymptomatic male. Bloods: CRP 0.6, WCC 5.3. Radiology: Day 3 CT was normal. No CXR.

Xia et al (Clinical)

Xia W, Shao J, Guo Y, Peng X, Li Z, Hu D. Clinical and CT features in pediatric patients with COVID-19 infection: Different points from adults [published online ahead of print, 2020 Mar 5]. Pediatr Pulmonol. 2020;10.1002/ppul.24718. doi:10.1002/ppul.24718

A case series of 20 paediatric patients with COVID-19 infection identified with COVID-19 NAT on pharyngeal swabs from Wuhan Children's Hospital. It reviews the clinical information and co-infections.

Clinical features: two thirds had a clear contact history. Incubation 24hrs-28 days of life. 13/20 had a cough, 12/20 had a fever. Bloods: 11/20 had (N) CRP, i.e. less than 3mg/L and 80% had PCT >0.05.

Radiology: On CT: Subpleural findings were seen in all 20 patients. 50% had bilateral findings, with a further 6/20 with unilateral findings. Consolidation with a halo in 50% of cases, considered as atypical signs in paediatric patient. Chloral hydrate was the primary sedative for CTs These were predominantly mild cases in the paediatric patients, with CXR adding little diagnostically. An early chest CT exam seemed to be necessary. 9/20 had coinfection, most commonly with mycoplasma (4/9) – although the 'flu B,'flu A or RSV accounted for almost all of the remainder

Despite this, the physical chest symptoms were mild, with retraction in one case, and another case with cyanosis.

The average length of stay 12.9 days. Some patients were managed on the basis of their CT alone. These are similar to those seen in adults.





Cai et al (Clinical)

Jiehao Cai, Jing Xu, Daojiong Lin et al, A Case Series of children with 2019 novel coronavirus infection: clinical and epidemiological features, Clinical Infectious Diseases, ciaa198, <https://doi.org/10.1093/cid/ciaa198>

This retrospective study examines 10 children diagnosed with confirmed COVID-19 between 19th Jan and 3rd February 2020 at the Children's hospital in Shanghai. The age range is from 3 months to 11 years. None had comorbidities. There were no severe cases.

Clinical features: The assumed incubation period (time from exposure to index case to developing symptoms) was between 2 – 10 days, but median (and mode) 7 days. With regard to symptoms, 7/10 had fever $>38^{\circ}\text{C}$, 6/10 had a cough, 4/10 had a sore throat, 3/10 had nasal congestion, 2/10 had rhinorrhea and 2/10 were sneezing.

Radiology: The chest x-ray was normal in 6/10. The rest had unilateral opacities.

Bloods: Lymphocyte counts were normal in 9/10, raised in one case. CRP ranged from 0.5mg/L to 35mg/L but was <10 for 7/10. Procalcitonin was normal (<0.25) in all children. 2 patients had a mild elevation of ALT (100U/L) or AST (142U/L and 51U/L)

Detection of SARS-CoV-2: Virus was found in NP/throat swabs in all patients, and the duration of shedding ranged from 6-22 days (Median 12 days). Stool shedding was prolonged, over 30 days in one patient. No urine was positive, and no serum positive.

Kai-Qian et al (Clinical)

Kai-Qian Kam, Chee Fu Yung, Lin Cui et al, A Well Infant with Coronavirus Disease 2019 (COVID-19) with High Viral Load, Clinical Infectious Diseases, ciaa201, <https://doi.org/10.1093/cid/ciaa201>

This was a case report of a single 6-month-old with a positive nasopharyngeal swab until D16 of admission to hospital. There had been household transmission. There was a positive NPA with rt-PCR on D1 of admission although the child was asymptomatic – daily swabs remained positive until D17. The child was febrile once during the course of admission although they remained asymptomatic. Blood and stool tests were positive on D2. They had essentially normal investigations except for a neutropenia.





Chen et al (Clinical)

Chen C. Coronavirus Disease-19 Among Children outside Wuhan, China [Internet]. Lancet Child and Adolescent medicine; Available from: https://papers.ssrn.com/sol3/papers.cfm?abstract_id=3546071


A pre-print, the information should be treated with caution until it has undergone peer review. This is a prospective case series of 31 paediatric cases of COVID-19 diagnosed at the Shenzhen Third Peoples hospital between Jan 16th and Feb 19th 2020. This made up 7.9% of all cases diagnosed in Shenzhen. They were all confirmed by PCR. None had been exposed to the seafood market in WUhan. The patients received nebulised interferon and, IV ribavirin or oral lopinovir/ritonavir. The median age was 6.75, with most patients (41.9%) aged 5-9. Followed by 0-4yrs (32.2%) and 10-14yrs (19.4%). 41.9% were male.

Clinical features: 12/31 Children were asymptomatic. Fever was observed in 14/31, Cough in 13/41, Sore throat in 2/31, Rhinorrhoea in 22/31 and diarrhoea in 2/31. Median duration of fever was 2 days, with a range of 1-9 days. Bloods: Lymphopaenia was not observed. Lymphocytosis occurred in 17/31 patients. CRP was elevated in 4/31 patients. Radiology: On admission 64.5% of CT were normal, with 25% having unilateral pneumonia and 9.7% having bilateral. During hospitalization one child developed a unilateral pneumonia whose radiography was initially normal. Outcome: 23 children had been discharged at the time of writing, and the remainder were well and afebrile.

Xu et al (Clinical)

Xu X-W, Wu X-X, Jiang X-G, et al. Clinical findings in a group of patients infected with the 2019 novel coronavirus (SARS-Cov-2) outside of Wuhan, China: retrospective case series BMJ 2020; 368 :m606


This study looks at a group of 62 patients with COVID-19 in a province outside of Wuhan (Hubei). 2 of these were children, aged 10 and 11. There is a lot of clinical data in the paper but it is not broken down by age, so we cannot make any inference on behalf of the paediatric patients.



Pan et al (Clinical)

Pan X, Chen D, Xia Y, et al. Asymptomatic cases in a family cluster with SARS-CoV-2 infection, The Lancet Infectious Diseases, 2020, [https://doi.org/10.1016/S1473-3099\(20\)30114-6](https://doi.org/10.1016/S1473-3099(20)30114-6).

This case study looks at another family cluster of COVID-19 involving asymptomatic patients. It involved a 3yr old boy who was positive for SARS-CoV-2 despite having no symptoms, normal bloods and a normal CT.





Wei et al (Clinical)

Wei M, Yuan J, Liu Y, Fu T, Yu X, Zhang Z. Novel Coronavirus Infection in Hospitalized Infants Under 1 Year of Age in China. Published online February 14, 2020. doi:10.1001/jama.2020.2131

This is a case series of, from Dec 8 2019 to Feb 6 2020, from China of 9 infants – all of whom had been hospitalised.


Clinical presentation: 4/9 fever, 2/9 mild URTI symptoms, 1/9 were asymptomatic. All had family members that were COVID-19 positive. There were no severe complications or ICU admissions.

CDC et al (Epidemiological)

Coronavirus Disease 2019 in Children – United States, February 12–April 2, 2020. MMWR Morb Mortal Wkly Rep. ePub: 6 April 2020. DOI: <http://dx.doi.org/10.15585/mmwr.mm6914e4>

This is the first USA CDC report of COVID-19 looking specifically at children, examining confirmed cases nationally between February 12th and April 2nd. Due to the extremely disparate nature of public health reporting in the USA, the data quality and availability for this report is highly variable. There is no information as to the basis on which tests were performed, whether for presentation to hospital, symptomology or due to contact tracing. This cohort is therefore likely extremely heterogeneous. Of the nearly 150,000 confirmed cases in the US at this time, 2,572 (1.7%) were in children. New York City had 33% of paediatric cases. The median age was 11y and males account for 57%. Nearly 33% of cases were in children aged 15 – 17yrs, 15% in children <1y, 11% in children ages 1 – 4y and 15% in children 5 – 9y. 91% of cases had exposure to a known COVID-19 case.

Data on signs/symptoms was only available for 11% of cases. Fever, cough OR shortness of breath were present in 73% of cases, with fever in 56%, cough in 54%, shortness of breath in 13%, rhinorrhoea 7.2%, sore throat 24%, vomiting 11% and diarrhoea 13%. They have not reported on “asymptomatic” cases due to incomplete reporting on symptoms. ICU admission was documented for 2% of cases. Hospitalisation was most common in infants (62%), with little difference between other age groups in regards to hospitalisation or ICU admission. From low numbers infants did not appear significantly more likely to be admitted to ICU. Underlying conditions were present in 23% of cases, most commonly respiratory (such as asthma), followed by cardiac conditions and immunosuppression. There are 3 deaths reported, but review is ongoing to determine whether COVID-19 was the cause. This patchy data from the US is useful as it closely resembles data from Chinese cohorts of children in regards to low frequency of severity and adverse outcomes. It confirms available data suggesting lower frequency of common symptoms in children as compared to adults.



Zhu et al (Epidemiological)

Zhu Y, Bloxham CJ, Hulme KD, et al. Children are unlikely to have been the primary source of household SARS-CoV-2 infections. medRxiv 2020;:2020.03.26.20044826. doi:10.1101/2020.03.26.20044826

A pre-print, the information should be treated with caution until it has undergone peer review.

This study includes a review of symptom frequency in children, but most interestingly examines available case series in the literature of family clusters of COVID-19 to determine what contribution is made of children to the chain of transmission. Clusters were taken from China, Singapore, the USA, South Korea and Vietnam, totalling 31 household transmission clusters. Of these cases, only 3 (9.7%) had a child as the index case. Considering a worst case scenario (whereby ALL infected children were the index case in their family and had been mislabelled as a secondary in some studies), still children would only account for 6/28 (21%) infection clusters. They compare this to the H5N1 epidemic where children were the index case in 54% of household clusters. This provides further evidence that children appear to have a fairly limited role in the transmission of COVID-19, which has implications for non-pharmaceutical interventions such as school closures.





Davies et al (Epidemiological)

Davies N, Klepac P, Lui Y et al. Age dependent effects in the transmission and control of COVID-19 epidemics. Pre print, first online March 24th 2020. (available <https://doi.org/10.1101/2020.03.24.20043018>)

A pre-print, the information should be treated with caution until it has undergone peer review. This is a mathematical modelling study from the London School of Hygiene and Tropical medicine, examining the explanation for the relatively low numbers of childhood cases of COVID-19. They assess three plausible explanations, including

- 1. Assortative mixing patterns or school closures decreasing mixing and spread between children.*
- 2. Children exhibiting lower susceptibility to infection.*
- 3. Children having a lower propensity to show clinical symptoms.*


They tested these hypotheses by fitting an age structured model to epidemic data from six countries (China, Japan, Singapore, South Korea, Italy and Canada). The details of the modelling and simulations are highly specialist, but essentially they found that there was a strong age dependence in the probability of developing clinical symptoms. There are many implications to this, including limited efficacy of school closures in halting the spread of the pandemic, and that regions with older populations may see disproportionate more cases, in particular during the latter stages of the pandemic. They note that understanding the role of subclinical infection remains vital to informing policy to stem the spread of disease. We should remember this is based on mathematical modelling, and further clinical and epidemiological information will be necessary to confirm or refute their hypothesis.

Bialek et al (Epidemiological)

Bialek, S & Sauber-Schatz, E. Severe Outcomes Among Patients with Coronavirus Disease 2019 (COVID-19) – United States, February 12–March 16, 2020. MMWR Morb Mortal Wkly Rep. ePub: 18 March 2020. DOI: <http://dx.doi.org/10.15585/mmwr.mm6912e2> - HG

Epidemiologic study of reported COVID-19 cases, by age group published by the United States's CDC for the period, February 12–March 16, 2020. Data includes hospitalization, intensive care unit (ICU) admission, and case-fatality percentages by age, for 2449 patients with confirmed COVID-19 PCR, including 123 cases aged <19 year old.

Of which, 1.6-2.5% hospitalisation rate, no ICU admissions, no deaths.





Livingston et al (Epidemiological)

*Livingston E, Bucher K. Coronavirus Disease 2019 (COVID-19) in Italy. JAMA
Published Online First: 17 March 2020. doi:10.1001/jama.2020.4344*

This is a helpful one page summary of data around COVID-19 numbers in Italy as of 15th March 2020.

Of note, there have been 22,512 cases of COVID-19 with 2026 (9%) being health care workers. There have been 1625 deaths (7.2%) of cases in Italy, which is a higher case fatality than rates from China and other countries so far. Below are two of the charts below which depict the age range and severity of COVID-19 infections. From a paediatric perspective, 1.2% of cases have been in patients <18 years old and remarkably there have been 0 deaths under 30yrs of age so far.

Choe et al (Epidemiological)

COVID-19 National Emergency Response Center, Young June Choe. Coronavirus disease-19: The First 7,755 Cases in the Republic of Korea. medRxiv 2020.03.15.20036368; doi: <https://doi.org/10.1101/2020.03.15.20036368>

This is a report of the first 7755 patients with confirmed COVID-19 in Korea as of March 13th. It is notable as Korea undertook one of the worlds most intensive strategies to community testing, which may give a better understanding of the proportions of different groups affected who may have had mild or subclinical infection and might otherwise not have been tested.

The finding of significance is that children made up a very small proportion of total cases, with only 75 (1%) under 9 years of age, and 405 (5.2%) aged 10–19 years. There were no deaths in patients under 30 years of age. This suggests not just low severity of infection in children, but a low attack rate with such low cases numbers.





Mizumoto et al (Epidemiological)

Mizumoto K, Omori R, Nishiura H. Age specificity of cases and attack rate of novel 1 coronavirus disease (COVID-19) 2. doi:10.1101/2020.03.09.20033142

A pre-print, the information should be treated with caution until it has undergone peer review.

This is a series of the 313 domestically acquired cases of COVID-19, in Japan, up until March 7th 2020. It looks at the ages of patients who acquired the disease and compares this to those exposed (n=2496) to estimate attack rates.

Of note, there was a significantly lower attack rate in children (7.2% in males and 3.8% in females) than in the older populations (up to 22% in 50–59 year olds). This attack rate in children is similar to that observed in Shenzhen, but much lower than observed in older adults in Japan. This suggests children are much less likely to acquire the disease than adults if exposed. This is at odds with the findings from Shenzhen, and the reason for this disparity is unclear.

Dong et al (Epidemiological)

Dong Y, Mo X, Hu Y, Qi X, Jiang F, Jiang Z, et al. Epidemiological Characteristics of 2143 Pediatric Patients With 2019 Coronavirus Disease in China. Pediatrics 2020:e20200702. doi:10.1542/peds.2020-0702

This landmark paper is a retrospective epidemiological study of 2143 pediatric patients with suspected or confirmed COVID-19 (Jan 16 – Feb 8 2020) from in and around Hubei province in China. Confirmed cases were diagnosed by PCR of NPA or blood or genetic sequencing from the respiratory tract or blood highly homologous with SARS-CoV-2. To be a suspected case you needed to be high risk (based on community exposure) with any 2 of: fever, respiratory symptoms or diarrhoea/vomiting; normal or lower white cell count +/- raised CRP; abnormal CXR. If you were medium/low risk for community exposure, you could still be a suspected case if you met any 2 of the above criteria and had other respiratory viruses excluded. Patients were classed according to severity.

There were 731 (34.1%) laboratory-confirmed and 1412 (65.9%) suspected cases. The median age was 7 years. There were 94 (4.4%) asymptomatic, 1091 (50.9%) mild and 831 (38.8%) moderate, accounting for 94.1% of all cases. Of note, the youngest patients (under 1yr) had the highest proportion of severe and critical illness (10.6%). However, this group also had the highest proportion of “suspected” disease (293/379) – of which we do not know how many had an infection with RSV, HPMV or Flu. This was peak bronchiolitis season. There was one death in a 14yr old boy, for which there are no clinical details available. The highest proportion of asymptomatic cases was in the 6-10yr olds (31.9%), for whom there was no recorded critical illness. Critical illness was uncommon in general (0.6% of all cases). The median time from illness onset to diagnosis was 2 days. Chest imaging was emphasized in delineating the severity (CXR and CT). There are also some interesting epidemiology graphs which essentially map to the well-described adult prevalence of disease and demonstrate Hubei as the epicentre.

This large cohort study provides reassuring data about the severity of illness of COVID-19 in children. There is an indication that younger infants may be most likely to be affected most severely, however, this cohort is highly likely to contain children with normal, severe, winter viral infections such as bronchiolitis. Critical illness was extremely rare.





Bi et al (Epidemiological)

Bi Q, Wu Y, Mei S, et al. Epidemiology and Transmission of COVID-19 in Shenzhen China: Analysis of 391 cases and 1,286 of their close contacts. doi:10.1101/2020.03.03.20028423

A pre-print, the information should be treated with caution until it has undergone peer review.

This was a fairly impressive study looking at contact tracing of 1286 contacts of 391 patients with COVID-19. Only 20 (5.1%) of the initial 391 cases were children, of which 2/3 were asymptomatic. They discovered a secondary attack rate of 15% for household contacts and 9.6% overall. The most important finding is that the rate of infection in children <10 years (7.4%) was similar to the population average (7.9%). This demonstrates that children are becoming infected at a similar rate to adults, despite rarely having symptoms.

Wu et al (Epidemiological)

Wu Z, McGoogan JM. Characteristics of and Important Lessons from the Coronavirus Disease 2019 (COVID-19) Outbreak in China. JAMA Published Online First: 24 February 2020. doi:10.1001/jama.2020.2648

A cornerstone paper outlining the initial epidemiological data from the outbreak (up to February 11th 2020). This paper gave us the first indication of the enormous impact of age on prognosis from the disease. It reports on 72,312 cases (44,672 confirmed and 16,186 suspected). Of these only 1% were aged <9 years (2% <19 years) with no deaths aged under 9 years.



Fuk-Woo Chan et al (Epidemiological)

Jasper Fuk-Woo Chan, Shuofeng Yuan, Kin-Hang Kok et al, A familial cluster of pneumonia associated with the 2019 novel coronavirus indicating person-to-person transmission: a study of a family cluster, The Lancet, 395, 2020, 514-523

This case study looks at a family cluster, including a patient who had not traveled to Wuhan. There was one child, aged 10 in the cluster. They were asymptomatic but had bilateral ground-glass opacities on x-ray with essentially normal bloods.

